RNI No. MPENG/2013/50212

SAIMS TIMES

Sri Aurobindo Medical College & P.G. Institute

Volume 09 Issue - 01 Monthly May 2021 Page-22 Rupees - 5



कोविड 19: झलकियाँ

SAIMS Role in Controlling COVID-19

प्रधानमंत्री श्री नरेन्द्र मोदी द्वारा आहूत कोविड–19 नियंत्रण बैठक में डॉ. विनोद भण्डारी आमंत्रित

प्रधानमंत्री श्री नरेन्द्र मोदी द्वारा आज दिनांक 19/04/2021 को विडियो कांफ्रेंसिंग के द्वारा देश के चुनिन्दा चिकित्सकों के साथ कोविड–19 के नियंत्रण हेतु एक महत्वपूर्ण बैठक आयोजित की गई। जिसमें मध्यप्रदेश से श्री अरबिंदो मेडिकल कॉलेज एवं पी.जी.इंस्टिट्यूट के फाउंडर चेयरमेन डॉ.विनोद भंडारी को भी आमंत्रित किया गया।

प्रधानमंत्री द्वारा यह बैठक कोविड–19 पर नियंत्रण के संबंध में चर्चा हेतु आयोजित की गई थी जिसमें देश के प्रमुख चिकित्सकों को आमंत्रित कर उनके सुझाव चाहे गये थे। मध्यप्रदेश से केवल डॉ.विनोद भंडारी को इस बैठक हेतु आमंत्रित किया गया। नीति आयोग के डॉ. वी.के. पॉल द्वारा बैठक में उपस्थित चुनिन्दा चिकित्सकों से अपने सुझाव आमंत्रित किये। डॉ. देवी शैट्टी, डॉ. नरेश त्रेहान एवं अन्य उपस्थित चिकित्सकों द्वारा कोविड के प्रभावी नियंत्रण हेतु अपने सुझाव प्रस्तुत किये गये।

डॉ.विनोद भंडारी ने बताया कि श्री अरबिंदो हॉस्पिटल में केवल मालवा के ही नहीं अपितु गुजरात, राजस्थान एवं समीपस्थ अन्य प्रदेशों से आयें मरीजों का सफलतापूर्वक उपचार कर उन्हें कोविड मुक्त कर अपने घर भेजा जा चुका है। वर्तमान में भी अरबिंदो हॉस्पिटल ने अपने सम्पूर्ण 1400 बिस्तरों को कोविड हेतु समर्पित कर सभी मरीजों का सफलतापूर्वक उपचार किया जा रहा है। कोविड महामारी के बदलते स्वरूप पर चर्चा करते हेतु डॉ.भंडारी ने बाताया कि गत वर्ष 2020 में 40 प्रतिशत कोविड मरीजों को ऑक्सीजन की आवश्यकता थी जिसमें 20 प्रतिशत अतिगंभीर स्थिति में थे। वहीं वर्तमान में अब 60 प्रतिशत मरीजों को ऑक्सीजन की आवश्यकता है और 35 प्रतिशत मरीजों को आई.सी.यू. की आवश्यकता है।

उन्हौंने बताया कि इन्दौर, भोपाल, जबलपुर एवं समीपस्थ अन्य शहरों में आई.सी.यू. बिस्तरों की संख्या बढ़ाना अत्यंत आवश्यक हो गया है। डॉ.भंडारी ने बताया कि इन्दौर शहर में ऑक्सीजन की अत्यंत कमी है और पूर मालवा एवं दूरस्थ क्षेत्रों से भी मरीज यहां उपचार को आ रहे है। अतः इन्दौर शहर को ज्यादा से ज्यादा ऑक्सीजन सप्लाय की जायें एवं ऑक्सीजन की कमी को जल्द से जल्द दूर किया जाये। डॉ.भंडारी ने बताया कि मरीजों को होम क्वेरेंटाईन कर डेंटिस्ट, फिजियोथैरेपिस्ट, इंटर्न एवं अंतिम वर्ष के नर्सिंग, पैरामेडिकल विद्यार्थियों एवं अन्य सहयोगी स्टॉफ की सहायता ली जायें।

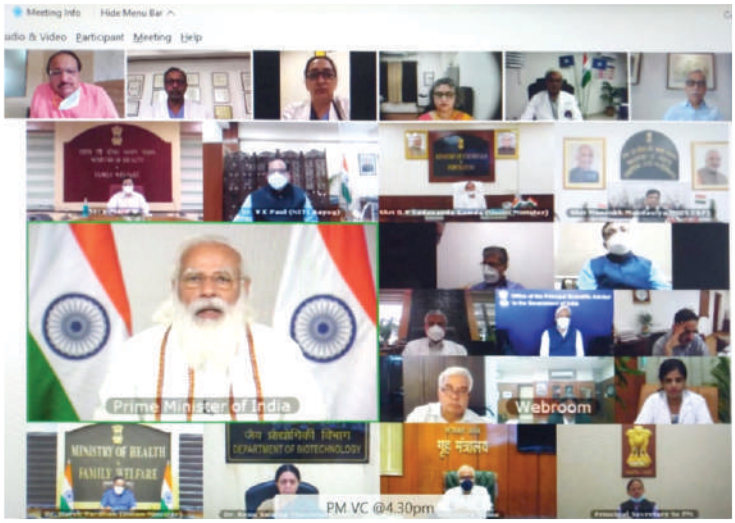

पीएम ने वीडियो कॉन्फ्रेंसिंग में इंदौर सहित देश के प्रमुख डॉक्टरों से की बात

'इंदौर में बढ़ाएं ऑक्सीजन सप्लाई'

पत्रिका PLUS रिपोर्टर

इंदौर ◆ प्रधानमंत्री नरेंद्र मोदी ने सोमवार को देशभर के प्रमुख शहरों के डॉक्टरों के साथ वीडियो कॉन्फ्रेंसिंग के माध्यम से चर्चा की। इसमें मप्र से इंदौर के अरबिंदो मेडिकल कॉलेज चेयरमैन डॉ. विनोद भंडारी भी शामिल हुए। इस ऑनलाइन बैठक में शामिल हुए डॉक्टरों से प्रधानमंत्री मोदी ने सुझाव भी मांगे। चर्चा में डॉ. देवी शेट्टी, डॉ. नरेश त्रेहान व अन्य डॉक्टरों द्वारा कोविड के प्रभावी नियंत्रण के लिए सुझाव प्रस्तुत किए गए। चर्चा में डॉ. भंडारी ने बताया कि पिछले वर्ष तक 40 प्रतिशत कोविड मरीजों को ऑक्सीजन की आवश्यकता होती थी जिसमें से 20 प्रतिशत अति गंभीर स्थिति में थे। वहीं वर्तमान में अब 60 फीसदी मरीजों को ऑक्सीजन की जरूरत है और 35 फीसदी को आईसीयू की आवश्यकता पड़ रही है। ऐसे में इंदौर शहर को ज्यादा से ज्यादा ऑक्सीजन सप्लाय की जाना चाहिए।

Hon'ble Chief Minister Shri Shivraj Singh Chauhan appreciated Dr Ravi Dosi for all the work for COVID treatment being done at SAIMS.

Message From The Desk Of Founder Chairman And Editor-in-chief

Sri Aurobindo University gives us the opportunity to serve the humanity. Presently, India is experiencing the second wave of COVID pandemic. The central and state governments are taking all the necessary steps.Sri Aurobindo Medical College and Hospital, a major centre for the treatment of COVID-19 patient, is fighting the COVID-19 pandemic in the best possible way and giving good results. I am pleased that we have been the part of COVID related meetings to combat the spread of COVID-19 with Hon'ble Prime minister Shri Narendra Modi and Hon'ble chief minister Shri Shivraj Singh Chauhan. Numerous authorities, patients and their relatives have expressed their gratitude for our efforts. It is all of you, my SAIMS and MOHAK family members who are working tirelessly to provide lifesaving care to patients. I would like to congratulate all of you for this.

I am delighted that SAIMS Times is now being published regularly on monthly basis. This newsletter will help in the dissemination of information about new updates and current events at our university. This issue specifically covers COVID-19 treatments, complications, and implications related articles based on the experiences gained at SAIMS. The previous issues introduced all of the heads of the institutes affiliated with Sri Aurobindo university as well as all heads of the department from Sri Aurobindo medical college and post graduate institute. The current issue features heads of the department from Sri Aurobindo dental, nursing and physiotherapy colleges.

I would like to extend a very warm welcome to the readership of our newsletter. I would also take this opportunity to thank our authors, editors, and everyone who contributed to help make our SAIMS Times a success. I encourage all faculty members and students to contribute to the future issues of the newsletter more and more. Your suggestions, comments, and proposals are always welcome.

Thankyou.

Dr. Vinod Bhandari

COVID-19 Mucormycosis


Dr. Jaishree Tapadia

During the second wave of Covid-19, after being positive, the impact is directly affecting eyes / patients. MUCORMYCOSIS (a disease) is making people blind. After getting treatment for COVID and recovery, a lot of patients come back complaining the inability to see properly. This is followed by swelling in eyes which eventually causes potential threat of blindness. This is a serious fungal infection which is going through the nose and directly impacting the brain and also leading to Brain Death.

This situation can be prevented by timely intervention during the initial stage. There is no known definitive remedy for it but the research is going on and some 30 injections are given to the patient for this particular problem.

For DIABETIC PATIENTS, this may be extremely fatal. Hence, it is advisable to get immediate MRI done for such patient.

WHAT NEEDS TO BE DONE ?

1. You need a team of diabetologist, an ENT surgeon, ophthalmologist who should be able to do endoscopic levage or clearing of fungus as much as possible for PNS (If disease is limited to PNS in early stages).
2. Start injection “Amphotericin B” as early as possible (dose on first day would be test dose around 0.5-1 MG per KG body weight, and if there is no adverse reaction then from next day increase the dose upto maximum of 5 mg per kg body weight per day along with renal monitoring (urine output creatinine) and electrolytes.
3. There should be tight sugar control with round the clock insulin.
4. If fungus reaches to orbit then ophthalmogical intervention (Can require enucleation in cases where there is complete ophthalmoplegia with no vision)

“Mostly the doctors receive patients at this stage and/or beyond that where there is brain involvement.”

PATHOPHYSIOLOGY OF MCR

SARS CoV-1 induces damage of pancreatic islets resulting in acute diabetes and DKA. This is a possible explanation for the “diabetogenic state” in SARS CoV-2 infection, as there is a high expression of angiotensin-converting enzyme 2 receptors in pancreatic islets, along with increased insulin resistance due to cytokine storm. Prevalence of DM (31%) and DKA (2%) in COVID-19 were higher compared to the national prevalence of type 2 DM and DKA in the general population in a UK study (7%). Recently, euglycemic DKA has also being reported in COVID-19 patients. The frequent use of corticosteroids in such patients may predisposed them to MCR.

Corticosteroid use is a key risk factor for opportunistic mycoses, including MCR. In addition to hyperglycemia, an alteration of iron metabolism occurs in severe COVID-19. Severe COVID-19 is a hyper-ferritinemic syndrome, but whether high ferritin is a marker of a severe systemic disease versus a modulator of pathophysiology is not known. Irrespective of its role, high ferritin levels lead to excess intracellular iron that generates reactive oxygen species resulting in tissue damage.

Cytokines, especially IL-6, due to severe infection and DKA, stimulate ferritin synthesis and fail to regulate iron export resulting in intracellular iron overload, further exacerbating the process. The resultant tissue damage leads to the release of free iron into the circulation. Iron overload and excess free iron seen in acidemic states are one of the key and unique risk factors for MCR. Another possible explanation for the association between COVID-19 and MCR is the “endothelialitis” observed in severe COVID-19. Autopsy series have shown more severe pulmonary vascular endothelial injury and new vessel growth in patients who died of COVID-19 than patients who died of influenza A (H1N1). Another postmortem series noted widespread endothelial injury in patients who died of multi-organ failure. Endothelial adhesion and penetration are critical early steps in MCR.

Interestingly, acidemic states and hyperglycemia induce the enthodelial receptor glucose-regulated protein (GRP 78) and the Mucorales adhesin spore coat protein homologs (CotH), creating a "perfect storm" for increased adhesion and penetration of Mucorales to the endothelium. Of interest, GRP 78 has been postulated as one of the receptors responsible for SARS-CoV-2 entry.

Watch out for Mucourmycosis in COVID-19 Patient

1 HIGH SUSPICION + 1 EARLY SYMPTOMS EARLY SIGNS + 3 EARLY DETECTION EARLY INTERVENTION = 4 BEST OUTCOME (REDUCED MORBIDITY & MORTALITY)

- Diabetes Mellitus
- Treated for COVID-19 with Corticosteroids
- Treated with Immunomodulators (Tocilizumab, Itolizumab)
- Treated with Mechanical Venitilation
- Long standing Oxygen therapy

- Sinus Headache
- Facial Pain
- Stuffy Nose
- Bloody nasal discharge
- Blurring of vision
- Double vision
- Dental Pain
- Loosening of teeth

- Facial swelling
- Facial skin discoloration
- Ptosis
- Proptosis
- Restricted eye movements
- Palatal discolouration
- Palatal Necrosis
- Brownish discharge from nose

- CBC
- Blood Sugar
- Renal Function Tests (S.Creatinine, BUN)

- Deep Nasal Swab - KOH Staining
- Nasal endoscopy - Biosy
- MRI - For extent involved
- CT Scan - PNS - To determine extent of involvement

- Medical management
- Strict Blood Sugar Control
- Antifungals :
  - Amphotericin B 1..5 - 5 mg/kg/day for 4-6 wks
  - Posaconazole Loading dose 300mg BD, 300 mg OD for 4-6 wks
- Early Surgical Debridement

Maxillofacial surgeon
- ENT Reference
- Ophthalmology Reference
- Neurological Reference

Dr. Jaishree Tapadia
Professor & Head
Dept. of Human Physiology,
Convener, Curricular-Sub-Committee (Phase-I) SAMC & PGI, Indore (M.P.)

CLINICAL SPECTRUM AND ATYPICAL MANIFESTATIONS OF COVID-19 IN CHILDREN AT PEDIATRIC DEPARTMENT, SAIMS

Introduction

Children and adolescents comprise only 1-2% of cases of Covid-19 cases worldwide. The vast majority of reported infections in children are mild or asymptomatic with only a few severe infections but being a tertiary care centre catering a wide variety of population, we have come across a wide variety of manifestations including atypical presentations, Multisystem inflammatory syndrome in children (MIS-C) and Pediatric Autoimmune Neuropsychiatric Disorders (PANS) in covid-19.

Clinical spectrum- We have admitted over 750 cases of COVID-19 in pediatric age group (upto 18 years) including neonates from April 2020 till date.

Severity of illness- The severity of illness was determined based on WHO & AIIMS criteria Mild illness- Sore throat,rhinorrhea, cough,No fast breathing.

Moderate illness (Pneumonia)- Fever with fast breathing (age based) : ≥60/min for <2months, ≥ 50/min for 2-12 months, ≥40/min for 1-5 years, ≥30/min for > 5years. No signs of severe pneumonia/illness.

Severe illness (Severe pneumonia) - Fever with pneumonia with any of these: Cyanosis, SpO2 < 90%, Increased respiratory efforts (grunting, severe retraction), lethargy, somnolence & seizures. Apart from this, other manifestations of covid-19 in children include arthralgia, myalgia, rashes, gastro-intestinal manifestations and acute CNS manifestations.

Severity distribution -

Severity	Number of cases (%)
Asymptomatic	87 (11.6%)
Mild	553 (73.7%)
Moderate	82 (10.9%)
Severe	28 (3.8%)

An increase in case number, severity and mortality was seen in this second wave, which is still continuing. Mortality was present in severe cases with comorbidities like obesity, diabetes mellitus, nephritic syndrome, pulmonary koch's and severe anemia, contributing only 1.2% of the total (9 children).

Age Distribution -

Age group	Number of cases (%)
upto 28 days	48 (6.4%)
1 month- 1 year	53 (7.1%)
1-5 years	172 (22.9%)
5-12 years	393 (52.4%)
12-18 years	84(11.2%)

Multi-system Inflammatory Syndrome in Children (MIS-C) - It is a severe multisystem inflammatory syndrome in previously healthy asymptomatic children related to covid-19 infection and clinical presentation is variable with significant gastrointestinal symptoms (diarrhea, shock, vomiting), cardiac symptoms (myocarditis, congestive heart failure, dilated coronaries), rash, coagulopathy and raised inflammatory markers. A incresed index of suspicion is required to diagnose such cases.

For children that fall under case definition, a multidisciplinary team approach is necessary to decide ongoing care as the disease manifestations can be significantly different.

We had 10 children diagnosed as MIS-C, 4 children(40%) had a poor outcome. 2 children had shock and 1 had guillain-Barré syndrome. Most of the children improved on IVIG and 2 non affording patients improved on high dose steroids.

Covid-19 related Pediatric Acute-onset Neuropsychiatric Syndrome (PANS) - It is very rare to suspect COVID 19 in a child mainly presenting with neurological symptoms, especially if respiratory symptoms are absent. The different neuro-psychiatric manifestations of Covid 19 in adults that have been reported are headache, dizziness, anosmia, ageusia, seizures, encephalopathy, stroke, acute disseminatedencephalomyelitis (ADEM), acute necrotizing encephalopathy, transverse myelitis, ataxia, neuralgia, Psychosis, and Guillain-Barré syndrome. We had 4 cases of covid-19 in children mainly presenting with neuro-psychiatric manifestations and the spectrum included meningitis, encephalitis, psychosis and guillain-Barré syndrome.

Neonates (0-28 days) - We had 48 covid positive neonates with majority being asymptomatic and mildly symptomatic requiring minimal care. 9 neonates required oxygen support and1 neonate (preterm /30 week/first of twin/dysmorphic facies/Necrotizing enterocolitis/sepsis) expired.

Conclusion - During the covid-19 pandemic, our department managed 750 children (<18 years) out of which 11.6% were asymptomatic, 73.7% had mild illness, 10.9% had moderate illness and 3.8% with severe illness. Mortality rate was 1.2% only. All severe cases were managed in ICU.Out of 10 MIS-C patients, mortality was 40%. Supportive care remains the mainstay of therapy for mild cases, while moderate and severe cases required antivirals and steriods. For MIS-C, IVIG was used.

So a high index of suspicion, good clinical skills and ICU care, dedication and commitment of entire team, superspeciality facilities andtimely management leads to a successful outcome in most cases.5

Dr. Gunjan Kela
(Professor & Head) SAIMS, Indore

Using innovation to save oxygen during current crisis

SAIMS has always been at the helm of the fight against COVID-19 in central India.We have received patients not only from Indore but from districts as far as Burhanpurand Jaipur.With the second wave being much bigger and deadly, the number of patients requiring oxygen and ventilators has been much higher than before.

Keeping in mind the oxygen crisis in the country, we have always been up to the task and have been taking lot of measures to save oxygen.We have an audit team that visits the wards and ICU to check on the oxygen usage, prevent wastage and leaks of oxygen. Apart from that we have started using some innovative measures to save oxygen and still provide the patient with enough oxygen to maintain his saturation.We have installed 15 PB 560 ventilators in our hospital which can work on low flow oxygen and can work with oxygen cylinder and even o2 concentrator. Compared to conventional ventilators, these consume less than a fourth of oxygen per minute.

Similarly, in place of NRBM plus nasal cannula, we have started using BAINs circuit or coaxial circuit in our wards and ICU.These are devices that were used in Anaesthesia practice in the past and can provide 100 percent oxygen with a flow rate of as low as 5 litres.We are using them with success in hypoxic patients with compliant lungs.

Dr. Subodh Chaturvedi
Chief Bariatric Anesthesiologist and COVID Critical Care In charge SAIMS

COVID ATTACKS NOT ONLY LUNGS, BUT HEART & BRAIN AS WELL POSTMORTEM OF A YOUNG MAN REVEALED THE FACT

A young man of 40 years was brought dead at Sri (SAIMS Hospital) on 06.05.2021. Since, the patient was a young fellow, the nearby police station was informed about his death and a postmortem was carried out.

The patient did not have any past history of Coronary Artery Disease (CAD), Cancer or any other serious illness. There was also no external injury mark all over the body.

When his body was opened his lung were found oily,slippery, bulky andoedematous clots were present all over the lungs. Dark blackish colour clotted blood was also present. Clotted blackish colour blood was also present in all the chambers of his heart and the brain was also studded with the clotted blood.

The above findings were strongly in favour of a typical case of Covid-19 infection, which was later confirmed by the history given by the relatives of the patient, who informed that the patient was having the complaints of breathlessness and fever for last 5-7 days and he was taking treatment at his residence. His C-Reactive Protein (CRP) levelswere also raised to around 120.

His postmortem findings give a fair idea of the severity of the Covid-19 infection and the organs which were very severely affected by Covid-19 virus.

BLACKISH COLOURED CLOTTED BLOOD RECOVERED FROM VENTRICLE OF HEART

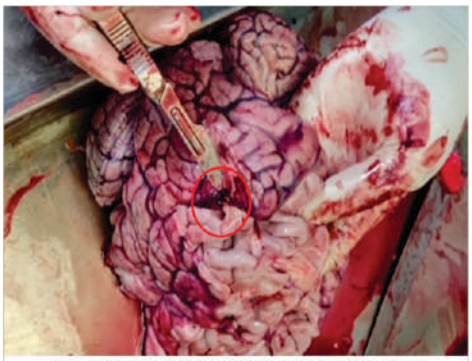

CLOTTED BLOOD IN THE VESSELS OF BRAIN

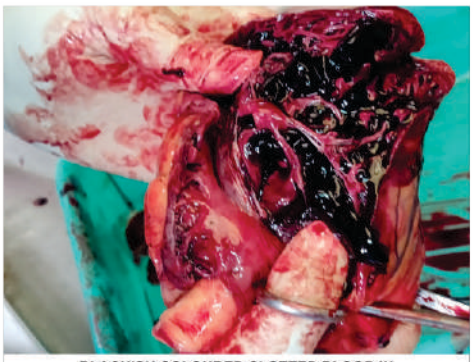

BLACKISH COLOURED CLOTTED BLOOD IN THE VENTRICLES OF HEART

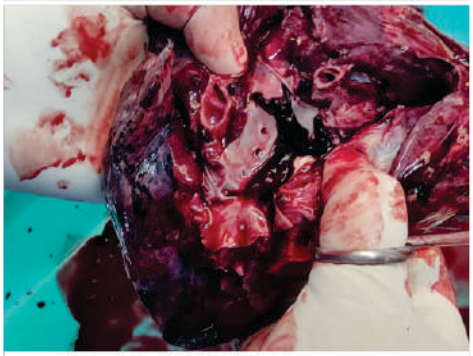

BLACKISH COLOURED CLOTTED BLOOD IN THE PULMONARY BLOOD VESSELS

GENERALISED BLACKISH COLOURED CLOTTED BLOOD IN THE COURSE OF PULMONARY BLOOD VESSELS

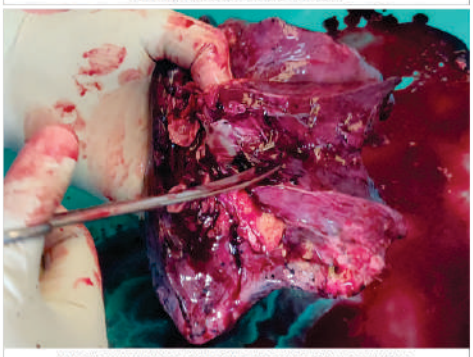

LUNG SHOWING BULKY OEDEMATOUS, SHINY & SLLIPARY SURFACE BLOOD CLOT

Dr Pankaj Nema
Assistant Professor, Department of Forensic medicine and toxicology, SAIMS&PGI

SAIMS
SRI AUROBINDO MEDICAL COLLEGE & P.G. INSTITUTE

FUNGAL SINUSITIS

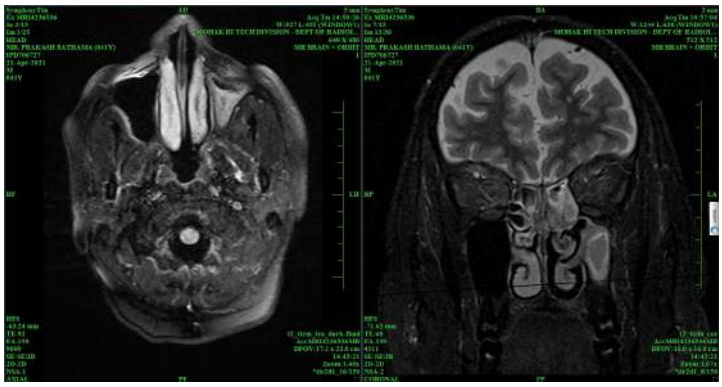

1.MRI images showing marked mucosal thickening in left maxillary and bilateral ethmoid sinuses – sinusitis and STIR hyperintense signals in soft tissue and muscle planes of bilateral orbits involving both intra and extraconal compartment – orbital cellulitis

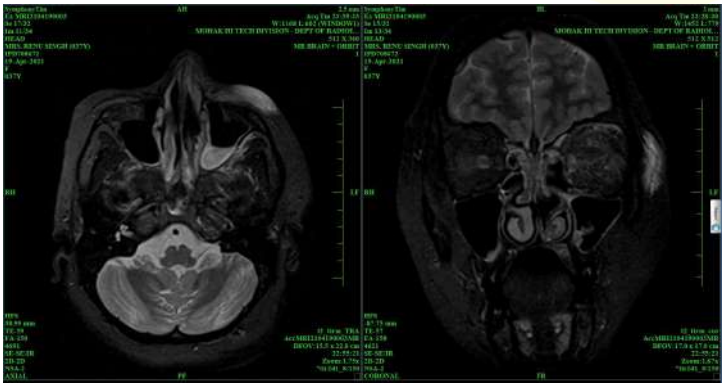

2.MRI images showing air fluid level in left maxillary sinus – acute sinusitis. STIR hyperintense signals in soft tissue and muscle planes of left orbit involving both intra and extraconal compartments and periorbital soft tissue – orbital and periorbital cellulitis. Also seen optic neuritis involving intraorbital part of left optic nerve.

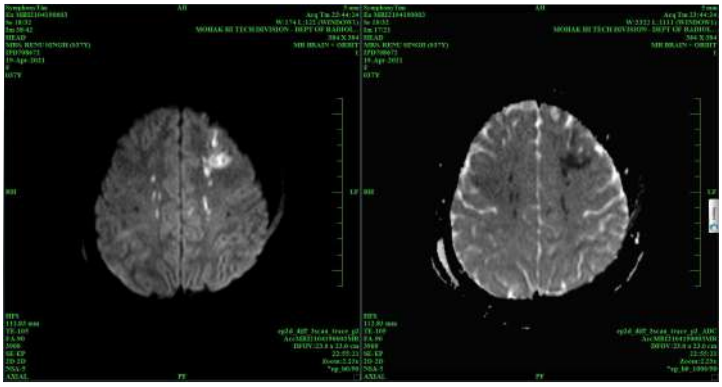

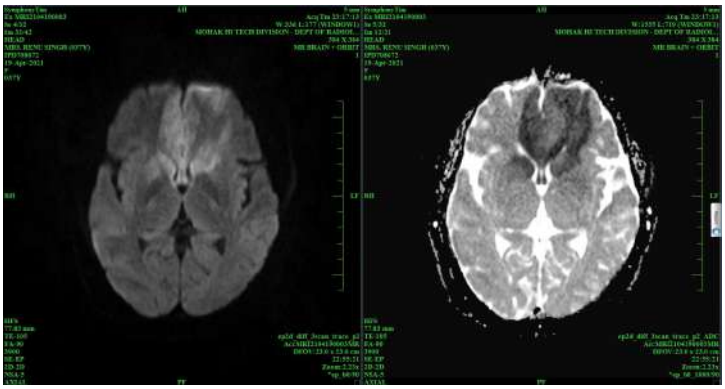

MRI images in the same patient reveal intracranial complications in the form of bilateral thromboembolic infarcts(post vasculitic) and frontal cerebritis.

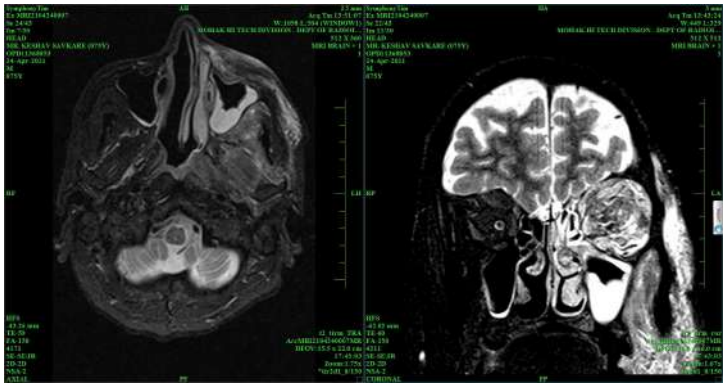

3. MRI images showing moderate to marked mucosal thickening in left maxillary and ethmoid sinuses – sinusitis and STIR hyperintense signals in soft tissue and muscle planes of bilateral orbits involving both intra and extraconal compartment and periorbital soft tissue – orbital and periorbital cellulitis. Also seen optic neuritis involving intraorbital part of left optic nerve.

4. MRI images showing air fluid level in both maxillary sinuses – acute sinusitis and mild mucosal thickening in bilateral ethmoid sinuses- chronic sinusitis. STIR hyperintense signals in soft tissue and muscle planes of both orbits involving both intra and extraconal compartments – orbital cellulitis

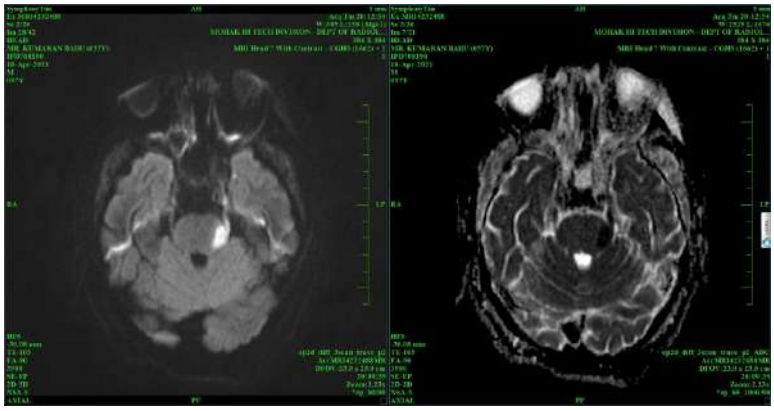

MRI images in the same patient show inclusion defect in left cavernous sinus- suggesting thrombosis. Area of diffusion restriction in left half of pons at the site of origin of left trigeminal nerve and in the trigeminal nerve- suggest cytotoxic edema could represent post vasculitic acute non-hemorrhagic infarct or nonhemorrhagic venous infarction due to venous congestion.

Declare the past, diagnose the present, foretell the future.— Hippocrates

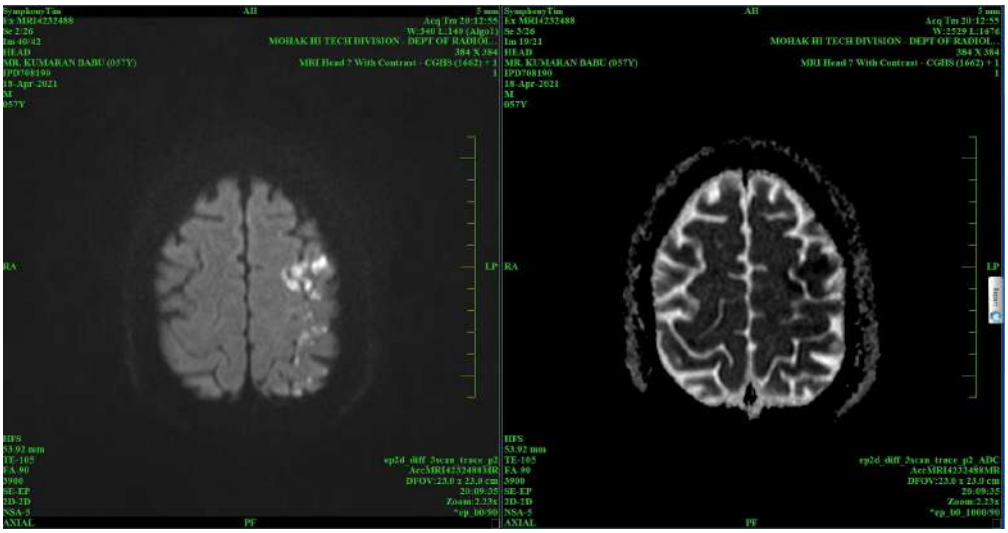

MRI images in the same patient reveal intracranial complications in the form of left fronto-parietal thromboembolic infarcts(post vasculitic)

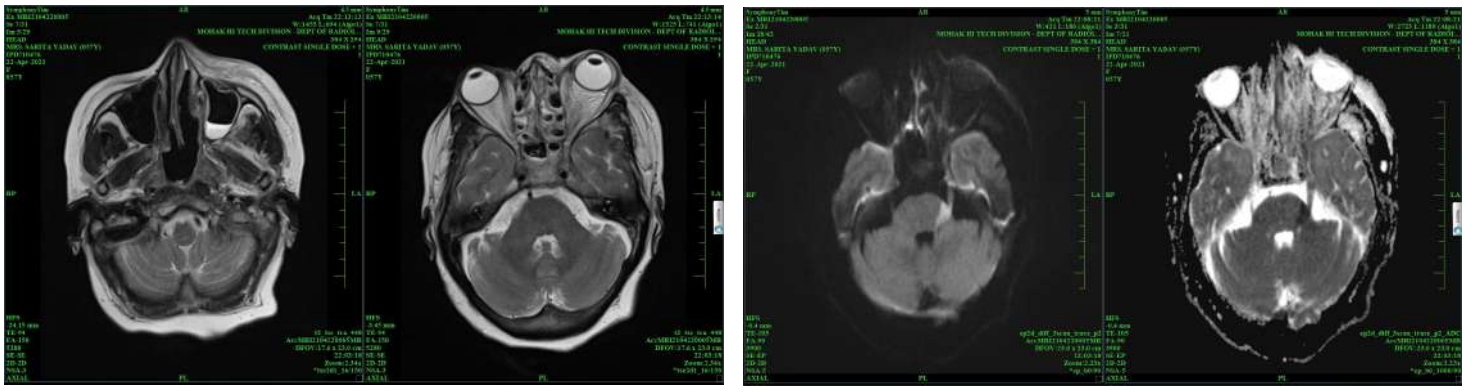

5.MRI images showing mild mucosal thickening with air fluid levels in left maxillary and both ethmoid and sphenoid sinuses – acute sinusitis. Area of diffusion restriction in left half of pons at the site of origin of left trigeminal nerve and in the trigeminal nerve- suggest cytotoxic edema could represent post vasculitic acute non-hemorrhagic infarct or nonhemorrhagic venous infarction due to venous congestion.

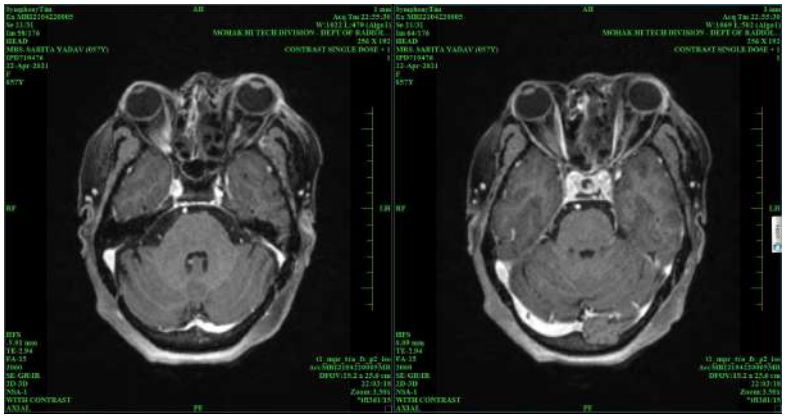

MRI images in the same patient showing abnormal meningeal enhancement along the clivus- meningitis and left cavernous sinus thrombosis

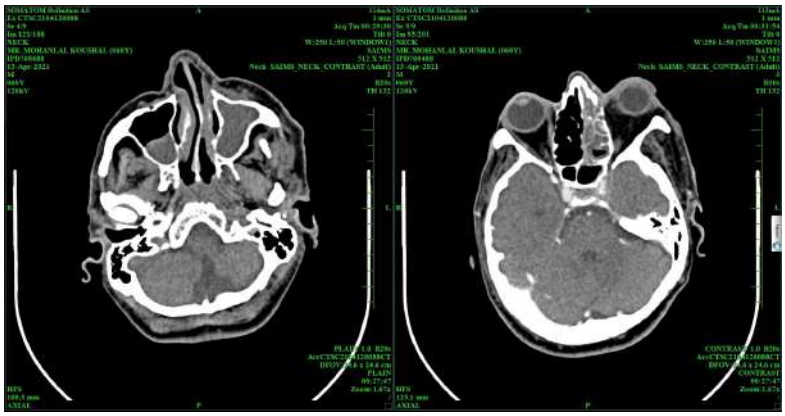

6.Axial CT images showing mucosal thickening in bilateral maxillary and left ethmoid sinuses –sinusitis. Inclusion defect in left cavernous sinus- suggesting thrombosis. Fat stranding seen in left orbit – orbital cellulitis

Institutional Advancement

VOICE CLINIC
Department of Speech & Hearing

Voice is something often taken for granted by many of us, including professional voice users, who do not pay attention to their voice until they develop a significant problem to it. These voice problems have an adverse effect on their ability to do their job.

A unique and first of its kind super speciality "VOICE CLINIC" has been started in Central India as a part of the Speech and Hearing department of Sri Aurobindo Institute of Medical Sciences, Indore, Madhya Pradesh, India.

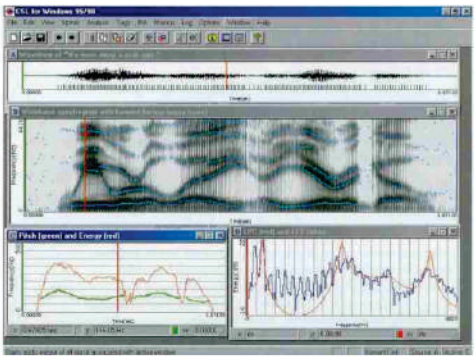

A team of Speech/Voice therapists, Laryngologists, Neurologists, Oncologists, Pulmono-logists and Radiologists are attached to the department to undertake a full range of investigations and out-patient management of various Voice, Airway, and Swallowing disorders.

VISION

Reach out to society by setting standards especially for those affected by Voice, Airway and Swallowing disorders.

OUR FACILITIES

Detailed investigation and management of voice problems through

Computerized Speech Laboratory (CSL): Provides detailed qualitative and quantitative acoustical voice analysis through three specialized modules (a) Voice Profiling (b) Multi Dimensional Voice Profile and (c) Motor Speech Profile.

Dr. Speech: It is a computerized voice & speech therapy product designed for personal and professional use. Through this we focus on improving speech, hearing, language, cognition, vocabulary, reading, and functional skills. We use modules like (a) Electro-glottography (b) Advanced multidimensional voice parameter detection and analysis (c) Real Speech (d) Pitch Master (e) Phonetogram and (f) Speech Therapy.

MISSION

To provide exceptional clinical care with compassion, technology, innovation and teaching.

SPECIALIZED FACILITIES

- The Professional Voice Clinic of SAIMS has been established with a purpose of acquainting users with the physiology of production of voice as well as educating them regarding voice injury.
- Most voice problems are managed successfully without surgery, through voice therapy (singing instruction, foreign and regional accent reduction, and executive speech skills) and medical care.
- We also focus on the prevention of vocal problems while improving voice skills through a customized program of vocal abuse reduction.
- We provide services for achieving the best possible voice among various conditions like hyper/ hypo functional voice disorders, neurological voice disorders as well as functional voice disorders.
- Specific therapy program such as resonant voice therapy, vocal function exercises, etc are also available.

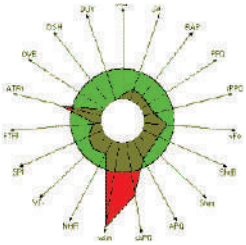

- If surgery is necessary, our experienced surgeons offer specialized techniques that reduce tissue harm and promote faster healing.

"The human voice is the most beautiful instruments of all, but the most difficult to play"

- Richard Strauss -

INVITED LECTURES

1. Dr Saket Jati was invited as speaker in IOACON 2021 JAIPUR to deliver talk on "Proximal Humerus Fractures, key to success: approach of choice on 5-7 March 2021.

2. Dr Saket Jati was invited as guest speaker in GLOBAL ORTHOPEDIC FORUM 20-21 March, PATNA to deliver a talk on Difficult Distal tibia fractures and also presented a case of management of Peri prosthetic fractures.

NEW FACULTY JOININGS

1) Dr Anurag Jain- MBBS, MS Orthopaedics, joined the department of orthopaedics as Assistant Professor
2) Dr Swapnil Vaidya - MBBS, MS Orthopaedics joined the department of orthopaedics as Senior resident.

PUBLICATIONS

Department of speech and hearing:

Singh NK, Sinha S, Keshree NK, Kothari S, Kumar S, Kumar P. Relative efficacy of veria and mastoidectomy techniques of cochlear implantation in preservation of sound-induced saccular responses. Int J Audiol. 2021 Apr 2:1-9. doi: 10.1080/14992027.2021.1905891.

31st May WORLD NO TOBACCO DAY

WORLD NO TOBACCO DAY

Anti Tobacco Slogan and Poster Contest

- Open to all faculty members, PG, UG of all streams
- One entry per person only.
- Language -English or Hindi.
- Slogan- not more than 15 words.
- Poster -A4 page size, multicolor - 8-1/4 x 11-3/4
- Over size posters will be rejected.

The entries to be sent to saimstimes@saimsonline.com
Last date for entries is 25th May.

The results will be announced on 31st May.
The selected slogans and posters will be published in 'SAIMS TIMES'.

SAIMS
SRI AUROBINDO MEDICAL COLLEGE & P.G. INSTITUTE

31st May WORLD NO TOBACCO DAY
TOBACCO - FACTS

- **TOBACCO –** is the most preventable cause of cancer and death in the world
- **TOBACCO –** causes approx. 13 lakhs death each year in India.
- **TOBACCO –** causes worldwide 8 million deaths each year.
- **TOBACCO –** most preventable cause of morbidity & mortality.
- **TOBACCO –** in all forms-Beedi, Cigarette, Pipe, Hookah, Gutka are harmful.
- **TOBACCO –** kills half of it users.
- **TOBACCO –** as per ICMR -out of 100 teenagers smoking today in India, 50 will eventually die of tobacco related diseases and it will be an early death.
- **TOBACCO –** Cigarette-a lethal cocktail of a horrifying list of toxic chemicals.
- **TOBACCO –** Cigarette smoke has 7000 chemicals, 250 known carcinogens/harmful substances.
- **TOBACCO –** there's nothing like safe, light, healthy cigarette.
- **TOBACCO –** E Cigarettes, ENDS, IQOS are all bad for health and banned in India.
- **TOBACCO –** most common cause of bad smell from mouth-Halitosis
- **TOBACCO –** leading cause of Angina, Myocardial Infarction.
- **TOBACCO –** can lead to Hypertension & Paralysis.
- **TOBACCO –** clogs arteries, leading to Peripheral Vascular Diseases, Gangrene etc.
- **TOBACCO –** leading cause of Breathlessness, COPD, Lung Cancer.
- **TOBACCO –** as per UICC Tobacco causes 13 different types of Cancer.
- **TOBACCO –** Oral Cancer has a very HIGH incidence in India because of the habit of chewing Tobacco.
- **TOBACCO –** Cancer is known to occur at the site, tobacco (quid) is kept in mouth.
- **TOBACCO –** Pregnant ladies should never take tobacco as it can lead to number of birth diseases / anomalies in the child-Mental Disorders, Cleft Lip and Palate,Squint etc.
- **TOBACCO –** is a major cause of Impotency.
- **TOBACCO –** can cause macular degeneration leading to Blindness.
- **TOBACCO –** use is a costly affair-not only the cost of tobacco product but also treatment cost due to tobacco related diseases.
- **TOBACCO –** is very addictive, its hard to quit but we have drugs to help QUIT.
- **TOBACCO –** Most people in the world are able to quit due to their will power, counseling, support of family & friends.
- **TOBACCO –** Cold Turkey method-maximum smokers quit by sudden decision to quit and not by gradual reduction.
- **TOBACCO –** and COVID-frequent hands, touching mouth for chewing tobacco or near lips for smoking can likely increase the infection chances.
- **TOBACCO –** and COVID-smokers at higher risk of lung complications due to already compromised smoker's lung.

Dr.Dilip Kumar Acharya
Prof. of Surgery
National Chairman-IMA Cancer and Tobacco Control Committee.

Occupational Therapist role in COVID 19
BEING OPTIMISTIC



This COVID-19 Pandemic has added tons of stress and burnout in individual's life. We as Occupational Therapist, working in COVID-19 Wards, focus on individual's mental health. We deals with different age group peoples and we try to engage them in recreational or leisure activities like singing, drawing, writing competitions & also providing virtual family support to give them a positive pleasurable stimulus, to look on the brighter side of the situations they are facing.

Apart from these, Occupational therapy practises safe bed mobility, Fall Prevention techniques in geriatric population, Energy Conservation techniques, Body scanning Relaxation technique, & Counselling in hospital settings.

FACULTY SECTION

ACRYLIC PAINTING ON CANVAS

Dr. Rakhi Sivakumar
Associate Professor, Department of Physiotherapy

FACULTY SECTION

फिर मुस्कुराएगा

अंधेरा है आज चारों ओर,
फैली है निराशा घनघोर
डर मत, वक्त है निकल जायेगा
चुनौतियाँ तो आएँगी जीवन में हर पल
इनको जीत कर ही, तू योद्धा कहलायेगा
थोड़ा–सा भरोसा रख तू खुद पर
थोड़ा–सा भरोसा रख तू रब पर
देर से ही सही वो चमत्कार दिखायेगा
यह दृश्य जो दिख रहा आज
यह कष्ट जो हो रहा आज
संयम रख थोड़ा सारे कष्टों के बाद
फिर तू मुस्कुराएगा, फिर तू मुस्कुराएगा

रामजी पाठक
आडियोलाजिस्ट, स्पीच एंड हियरिंग विभाग

An Ode to the Nurse.....In Covid Times

While a bit more applause we did receive,
You held strong, your stamina did not decrease.
The sweaty PPE, you donn daily,
Sincere in your duty, risking family.
Long periods of relentless work,
Your responsibilities you did not shirk.
Caring Covid patients with compassionate attitude,
Whether ICU or wards, you worked without lassitude.
Patient nursing care, till the Covid battle won,
Unsung hero, you sure are the one.

Dr. Swati Mulye
Department of Paediatric

STUDENT SECTION

फिर सवेरा आयेगा

वक्त बुरा है मगर एक अंधेरी रात के बाद
फिर सवेरा आयेगा
तू चलता रह मुसाफिर अपनी मंजिल को पहुँच ही जायेगा।
न डर तू सुनसान रातों से, ना ही खामोश सन्नाटों से
क़ाफिर तो क़ाफिराना हो ही जायेगा।
बस एक बार गुज़र जा इन तूफ़ानों से
खुद में ही बेपनाह है, तू एक सफर की राह है तू
ऐ परिन्दे आँख उठा, पंख फैला और देख उस आसमाँ को
बुला रहा है, जो तुझे अपने आँगन में उड़ान के वास्ते
लहरों से भी पार तू हो जायेगा, डूब जा उन बहारों में
क्यों कि कल सवेरा आयेगा, उसका खुदा तू ही बन जायेगा
तू बस चल पड़, इन कदमों के जूनून को धीमा ना कर
दिल के आसमाँ को निराश न कर
साथी मिलेंगे कई इस जहाँ में
पर जो तुझमें है वो कहीं नहीं।

साक्षी ए.शाह,
बीपीटी 2018

Essence of Life

Let the springs come to your door, with colourful petals over all...
Let the rain showers on you like drops of pearl, with all smiles in your soul..
Let the winters arrive with soft snow in your window, with lots of happiness and no sorrow..
Let the summer fill you with pure sunshine, just bath in it by closing your eyes..
Let the winds to blow thy despair and dejection,
Fill thyself with blooming freshness..let go away all imperfection..
Life meant to be a once.. make moments revive..
Let sing, smile and sway.. spread positive vibes..
Let love that lovable with hugs and kisses...
Take drive to success, make true your wishes...

Dr. Amresh Kumar
JR 3
Radiation oncology department

Flash of IMA Activities

IMA Indore: The frontline corona worrier society, need of hours

We all are eye witness for corona pandemic, its gravity of harm, its consequences and many more for last almost one year. For whole year, we all were feeling helpless as far as its modality of treatment and management was concerned. We know, vaccination is one of the best and effective strategy to combat such infectious disease at large scale. But vaccination itself has its own challenges like its development, safety assessments, and its production in sufficient amount, its secure transportation and ultimately convincing public for vaccination. Though we are armed with two Indian made vaccines, which are safe and effective but main challenge was to do public awareness about vaccinations. This is the major component for its success where IMA Indore has done its outstanding efforts.

The first challenge was to vaccinate all IMA members and relative healthcare staff. This was useful in two ways ; first, it will safeguard our first line workers as they are on highest risk to get infected. Second, this will act as role models for others to accept vaccination program without undue anxiety. To Fulfill this, we and our IMA members especially IMA president Dr Satish Joshi, secretary Dr Sadhna Sodani, Clinical Secretary Dr Manoj Banshal, Dr Natwar sharda, Editor Dr Rakesh jain, Dr A K pancholia and others set an example by pioneering vaccination drive. This was followed by a marked rise in number of vaccinations throughout Indore and surrounding area. As of now, nearly all IMA members are fully vaccinated and safe.

Beyond this, we IMA Indore arranged many virtual gatherings, small personal meetings for public and healthcare workers to propagate the facts and safety of vaccination. We used social media, print and visual media to propagate the right information about vaccination to cover maximum possible of our citizens.

It is the combined and determined efforts of IMA Indore, who ignited the light of vaccination to overcome the darkness of covid pandemic with safety, surety and successfully and its results will definitely be full of joy for mankind.

Long live IMA,

Dr Rakesh Jain	Dr Sadhna Sodani	Dr Satish Joshi
Editor	Secretary	President

CASE REPORT 1

Carcinoma of cervix with metastasis to abdominal wall: A rare case report

Authors: Department of Radiation Oncology, SAIMS, Indore

We report a rare case of 47year female operated for cervical squamous cell carcinoma presented with left abdominal wall metastasis without loco-regional recurrence and sparing visceral organs such as the lung, liver, and brain.

A 47 yr old lady initially presented with complaints of backache, bleeding p/v, white discharge. USG revealed anteverted uterus, 15mm endometrium and bulky cervix and Pap smear examination identified moderate dysplasia. She underwent hysterectomy with bilateral salphingo-oophorectomy in April 20 for Ca cervix. Gross examination of cervix showed fungating growth 3.5x3x2 cm. HPE revealed grade 1 squamous cell carcinoma cervix with perineural invasion and entire myometrium invaded by tumor. She was administered 55Gy/25# RT and 1 sitting of intravaginal brachytherapy (IVBT) with 7 Gy/# in June 2020. She was then put on regular follow-up. After two months she presented with complaints of abdominal wall mass.

MDCT of abdomen and pelvis revealed metastatic deposit involving peritoneal surface of anterior abdominal wall, left paramedian umbilicus and infra umbilical region measuring 14 and 29x28x25 mm. Metastatic deposits in bilateral rectus abdominis, conjoint tendon and supra umbilical level measuring 65X58X72mm.

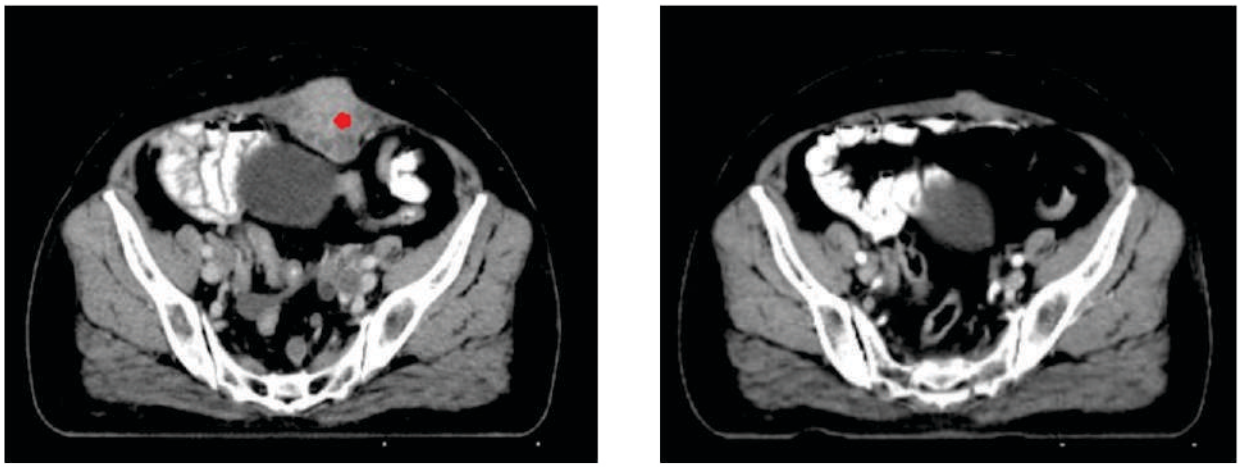

Biopsy from the left upper abdominal mass revealed metastatic deposit. Following which chemotherapy was planned.

She completed 6 cycles of chemotherapy with paclitaxel & carboplatin (260+600mg) by March 21 and there is 5X5cm mass palpable in left hypochondrium on follow-up. She was then put up for surgical opinion for radical excision and then patient is to be planned for further management with radiotherapy.

As prognosis in these cases is usually poor and due to less reported cases of such instances exact outcome is still unestablished. In our experience, we suggest aggressive follow up post-surgery for any abdominal wall recurrences and the treatment of metastasis usually includes a platinum-based chemotherapy, and/or radiotherapy. For the abdominal metastasis, we managed this case with adjuvant chemotherapy and very close follow-up and surgical opinion for radical excision and then further to be planned for management with radiotherapy.

To conclude, abdominal wall metastasis from cervical cancer is rare but it's important to diagnose and intervene in these cases because of poor outcome. Our experience suggest treatment with radiation therapy and chemotherapy though challenging but has significant better outcome, since extensive surgery is challenging and reconstruction further complicate the approach. These cases necessitate multidisciplinary approach and stringent follow-up.

CASE REPORT 2

Recurrent Dermatofibrosarcoma of Anterior Chest Wall

Authors : Dr.Sanjay Desai, Dr Vinod Dhakad, Dr Bonny Joseph, Dr Sandeep Ghosh, Dr Dhruv Patel, Dr Elroy Saldanha, Dr Varun Prakash, Dr Harshadeepthi Mamidala, Department of Surgical Oncology, SAMC & PGI

A 35-year-old female patient presented with recurrent swelling in the anterior chest wall. First noticed 8 years back, insidious in onset and gradually progressive in nature. FNAC was suggestive of myxoid spindle cell lesion. She underwent excision in 2019. Postoperative biopsy report was suggestive of fibromatosis. Swelling recurred 3 months after the surgery. Re-excision was done for the same in February 2020, biopsy report was fibrosarcoma ex dermatofibrosarcoma. Swelling again recurred 5 months later. She presented to SAIMS Surgical Oncology OPD for further management. There was no history of weight loss or cough o rbreathlessness. P2L2. Last childbirth 10 years back, normal delivery. No history of any comorbidities.

Examination revealed large exophytic lesion 15 x 15 cm in anterior chest wall and epigastric region, firm, non-tender, fixed to chest wall. With healed surgical scar over the skin. Also, two separate swelling within 5 cm of main swelling, largest measuring 2 x 3 cm. No other swelling anywhere else. No axillary adenopathy. Bilateral air entry was equal and clear.

CECT chest suggested well defined lobulated large exophytic heterogenously enhancing mass lesion in epigastric region arising from left anterior chest wall adjacent to anterior costal cartilage of 4th and 5th rib, 10.3 x 7.1 x 4.7 cm. Similar enhancing pattern lesion subcutaneous location near the first lesion 1.6 x 1.6 x 2cm.

She underwent wide local excision of the lesion with resection of medial portion of lower ribs and lower part of sternum, which was found to be adherent to the lesion intraoperatively. The resultant defect was closed with bone cement, sandwiched between two polypropylenemesh and fixed with polypropylenesutures. The soft tissue covering was achieved by raising bilateral pectoralis major myocutaneous flaps. Histopathology report was dermatofibrosarcoma protuberans with clear margins. Postoperative period was uneventful and she had a full recovery and was discharged on 10th postoperative day.

Dermatofibrosarcoma protuberans is a very rare connective tissue malignancy arising from the dermis. Less than 0.1% of all tumors, it is considered the most common cutaneous sarcoma. It's a slowly growing tumor which rarely spreads beyond the skin. It is considered locally aggressive and has a high tendency for local recurrence. Small lesions are treated with Mohs micrographic surgery and larger lesion need multidisciplinary approach with wide excision with reconstruction. Postoperative adjuvant radiotherapy is shown to reduce recurrence rates. Most recurrence happens within first three years and there after incidence declines slowly. Hence, long-term follow-up is essential in these cases.

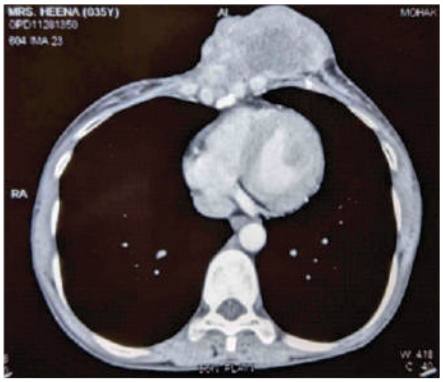

CASE REPORT 3

Role of Subjective Hearing Evaluation in Deciding Cochlear Implant Candidacy Among a Rare Case with Auditory Nerve Deficiency: Case Report

Author : Dr. Digant Patni, Nirnay Kumar Keshree, Mittali Joshi, Bhupendra Kurmi

A four year old male child with a bilateral profound sensorineural hearing loss was assessed for candidacy of cochlear implantation. Audiological and ENT examination confirmed that the child met the criteria for cochlear implantation. Computed tomographic scanning and magnetic resonance imaging (1.5 tesla) of temporal bone study revealed deficient apical turn of cochlea with normal basal turn on either side suggesting cochlear malformation associated with stunted/hypoplastic lateral, superior, posterior semicircular canal and absent of cochlear nerve .

Cochlear implant (CI) is contraindicative in cases with cochlear nerve aplasia as the device bypasses the function of ear till cochlea only. In such cases only viable treatment option left is the auditory brainstem implant (ABI) which bypasses the auditory system till auditory nerve. However, ABI is recommended only when no or limited benefit is received from CI and/or hearing aid in persons with hearing impairment.

Imaging techniques sometimes cannot delineate the accurate status of auditory nerve. Hence, conditioned play audiometry repeated thereafter to re-evaluate the auditory responses. Audiogram showed consistent behavioral responses at low and mid frequency at higher intensities. Aided play audiometric results also showed benefit from the hearing aid. These consistent auditory responses are suggestive of presence of auditory nerve thus allowing auditory stimulus to reach the auditory cortex.

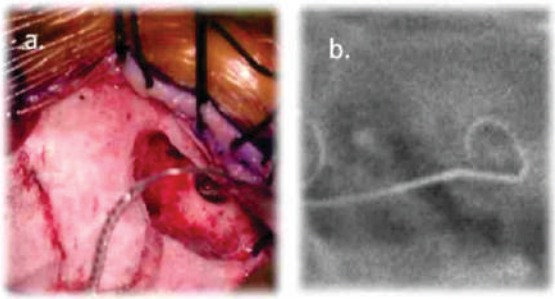

Fig 1: a) Cochlear Implant electrode insertion, b) Post opt X-Ray of temporal bone

Based on the above findings, surgeon operated right ear with cochlear implant (Fig 1). Intra-operative impedance and neural response telemetry (NRT) was carried out to assess device functioning and neural responsiveness of the auditory nerve. Neural responses were present across all the electrodes (Fig 2) from 1 (basal) to 22 (apical) which strongly suggests that all electrodes are within cochlea and current generated by active electrodes of cochlear implant are received by the auditory nerve. Thus, the findings correlates with the results of subjective hearing evaluation and re-confirms the presence of the auditory nerve.

Post operative initial activation of the device revealed presence of robust neural responses which validates the above findings. Currently, post three month of device activation, child is able to access speech sounds across the speech spectrum. Hence, to sum up, in such cases subjective hearing evaluation plays a major role in adjunct to the radiological findings in order to select appropriate implantable hearing prosthesis and achieve optimal hearing outcomes.

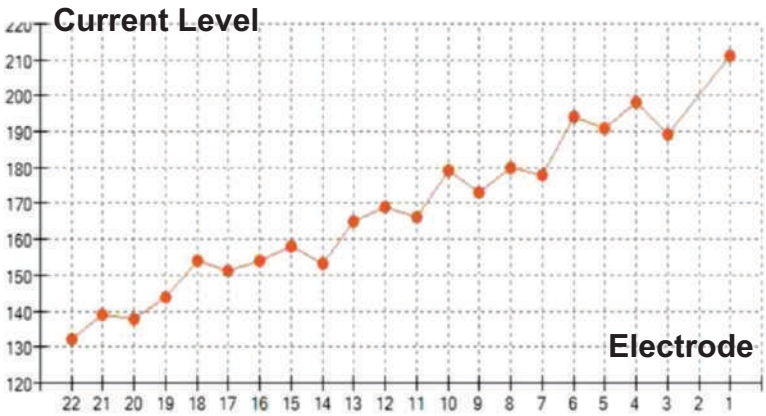

Fig2. Intra-Opt Neural Response Telemetry findings.

CASE REPORT 4

Two-stage revision of infected hip arthroplasty using an antibiotic spacer

Author: Dr. Pradeep Choudhari Professor and head, Dr Neeraj Jain Assistant Professor, Dr Mohit Mahoviya Assistant Professor, Department of Orthopaedics.

38/M came with complain of pain and pus discharge from right hip since 6 months, patient was an old operated case of uncemented total hip replacement right with prosthesis in situ, operated elsewhere 3 years ago. Examination showed discharging sinus with thick foul-smelling discharge from postero-lateral aspect of right thigh. Pus culture taken showed growth of Methicillin sensitive Staphylococcus aureus with elevated TLC, ESR and CRP. Prosthesis removal was done using flexible osteotomes, followed by thorough debridement and antibiotic spacer placement. Patient was administered intravenous antibiotics for 3 weeks followed by 3 weeks of oral antibiotics. TLC, ESR and CRP were repeated after 6 weeks which came normal and revision uncemented total hip arthroplasty was performed. At 1 month follow up patient was walking full weight bearing without support and showed no signs of infection.

Pre operative X-Ray and clinical image with visible discharging sinus

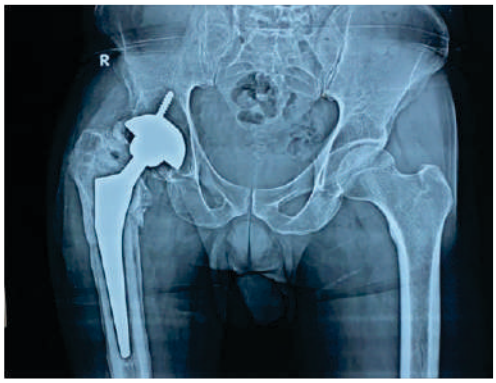

Immediate post-operative X-Ray-Revision arthroplasty

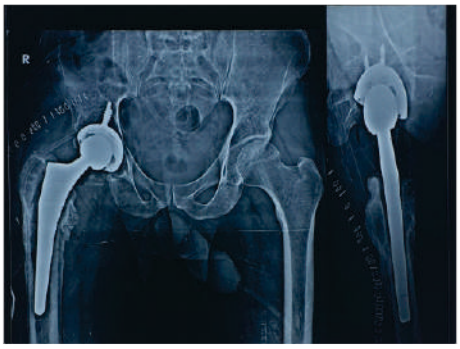

Antibiotic spacer placement following prosthesis removal and debridement

1 Month follow up X-ray

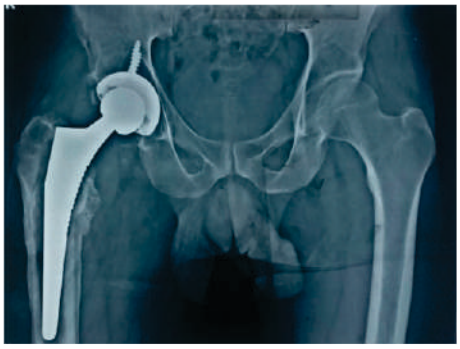

CASE REPORT 5

Modified quad helix along with obturator (A Clinical Innovation) for the correction of speech & swallowing pattern throughout the orthodontics treatment in cleft lip and cleft palate patients

Author – Dr. Ashish Garg, Dr. Agraj Sharma, Dr. Rakesh Thukral, Dr. Amit Tripathi, Dr. Sunita Marothiya, Dept of Orthodontics & Dentofacial Orthopedics

A 17-year-old female patient reported to Department of Orthodontics and Dentofacial Orthopedics with a chief complaint of forwardly and irregularly placed tooth in upper and lower front tooth region and presence of oro-nasal communication resulting into difficulty of speech and swallowing. She has undergone surgery for repair of cleft palate 13 years back which resulted in formation of 2 oro-nasal fistulae measuring 2-3 mm and 5-6 mm in diameter. On clinical finding, patient had convex profile, protrusive lips, constricted maxillary arch, crossbite present on right posterior region, sever crowding in upper anterior region and presence of two oro nasal fistulae. CBCT findings : revealed two welldefine hypodensities (osseousdefect) in anterior palate and junction of hard & soft palate, extending to include the floor of nasal cavity and oropharynx.

Treatment plan- Case started with fixed orthodontic appliance with cementation modified quad helix along with obturator in maxillary arch as we needed an appliance which will work both as obturator (for correcting speech and swallow throughout the treatment) and quadhelix which can produce desired expansion for correction of crossbite in right posterior region.

Now after 12 months of treatment, we have a patient with miraculous results having consonant smile arc, correct transverse and sagittal arch relation. Now, further treatment involves extraction of upper and lower premolars for correction of proclination of teeth to get ideal profile.

PRE-TREATMENT PHOTOGRAPHS

MODIFIED QUAD HELIX ALONG WITH OBTURATOR

PRESENT STAGE PHOTOGRAPHS

SAIMS : DEPARTMENTAL HEADS

COLLEGE OF DENTISTRY

DR.PALLAV PATNI
Conservative Dentistry
& Endodontics

DR.GEETI VAJDI MITRA
Oral & Maxillofacial
Surgery

DR. TANVI DOSI
Oral Medicine, Diagnosis
& Radiology
(as Department In Charge)

DR.SHRADHA JAISWAL
Oral Pathology
& Microbiology

DR. ASHISH GARG
Orthodontics &
Dentofacial Orthopaedics

DR.UPDESH MASIH
Pediatric &
Preventive Dentistry

DR.KANTESHWARI I. K.
Periodontology

DR. ANUP VYAS
Prosthodontics,
Crown & Bridge

DR. SANDESH N
Public Health Dentistry

COLLEGE OF NURSING

DR SUMIT PADIHAR
Child Health Nursing

DR RAJNI UDENIYA
Community Health Nursing

MR NILESH MISHRA
Medical Surgical Nursing

MR BASIL VARGHESE
Mental Health Nursing

DR. CHINTAMANI CHOUHAN
Obstetrics & Gynecology Nursing

COLLEGE OF PHYSIOTHERAPY

DR RAJNI PAWAR
Cardio Physiotherapy

DR RAKHI SIVAKUMAR
Gynae Physiotherapy

DR DEEPTI GARG
Neuro Physiotherapy

DR DUSHYANT K. SINGH
Ortho Physiotherapy

DR SHEKHAR MODAK
Sports Physiotherapy

SAIMS TIMES

Editor-in-Chief, Publisher, Printer and owner Dr. Vinod Bhandari.

Printed at Agniban 121 Devi Ahilya Marg, Indore, Publish By Saims Campus Indore Ujjain State Highway, Sanwer Road, Indore M.P. Ph.: 0731-4231000

Web : www.saimsonline.com Email : saimstimes@saimsonline.com